

## ORIGINAL ARTICLE

# Zika Virus Infection in Pregnant Women in Rio de Janeiro — Preliminary Report

Patrícia Brasil, M.D., Jose P. Pereira, Jr., M.D., Claudia Raja Gabaglia, M.D., Luana Damasceno, M.S., Mayumi Wakimoto, Ph.D., Rita M. Ribeiro Nogueira, M.D., Patrícia Carvalho de Sequeira, Ph.D., André Machado Siqueira, M.D., Liege M. Abreu de Carvalho, M.D., Denise Cotrim da Cunha, M.D., Guilherme A. Calvet, M.D., Elizabeth S. Neves, M.D., Maria E. Moreira, M.D., Ana E. Rodrigues Baião, M.D., Paulo R. Nassar de Carvalho, M.D., Carla Janzen, M.D., Stephanie G. Valderramos, M.D., James D. Cherry, M.D., Ana M. Bispo de Filippis, Ph.D., and Karin Nielsen-Saines, M.D.

## ABSTRACT

**BACKGROUND**

Zika virus (ZIKV) has been linked to neonatal microcephaly. To characterize the spectrum of ZIKV disease in pregnancy, we followed patients in Rio de Janeiro to describe clinical manifestations in mothers and repercussions of acute ZIKV infection in fetuses.

**METHODS**

We enrolled pregnant women in whom a rash had developed within the previous 5 days and tested blood and urine specimens for ZIKV by reverse-transcriptase–polymerase-chain-reaction assays. We followed the women prospectively and collected clinical and ultrasonographic data.

**RESULTS**

A total of 88 women were enrolled from September 2015 through February 2016; of these 88 women, 72 (82%) tested positive for ZIKV in blood, urine, or both. The timing of acute ZIKV infection ranged from 5 to 38 weeks of gestation. Predominant clinical features included pruritic descending macular or maculopapular rash, arthralgias, conjunctival injection, and headache; 28% had fever (short-term and low-grade). Women who were positive for ZIKV were more likely than those who were negative for the virus to have maculopapular rash (44% vs. 12%,  $P=0.02$ ), conjunctival involvement (58% vs. 13%,  $P=0.002$ ), and lymphadenopathy (40% vs. 7%,  $P=0.02$ ). Fetal ultrasonography was performed in 42 ZIKV-positive women (58%) and in all ZIKV-negative women. Fetal abnormalities were detected by Doppler ultrasonography in 12 of the 42 ZIKV-positive women (29%) and in none of the 16 ZIKV-negative women. Adverse findings included fetal deaths at 36 and 38 weeks of gestation (2 fetuses), in utero growth restriction with or without microcephaly (5 fetuses), ventricular calcifications or other central nervous system (CNS) lesions (7 fetuses), and abnormal amniotic fluid volume or cerebral or umbilical artery flow (7 fetuses). To date, 8 of the 42 women in whom fetal ultrasonography was performed have delivered their babies, and the ultrasonographic findings have been confirmed.

**CONCLUSIONS**

Despite mild clinical symptoms, ZIKV infection during pregnancy appears to be associated with grave outcomes, including fetal death, placental insufficiency, fetal growth restriction, and CNS injury.

From Fundação Oswaldo Cruz, Rio de Janeiro (P.B., J.P.P.J., L.D., M.W., R.M.R.N., P.C.S., A.M.S., L.M.A.C., D.C.C., G.A.C., E.S.N., M.E.M., A.E.R.B., P.R.N.C., A.M.B.F.); Biomedical Research Institute of Southern California, Oceanside (C.R.G.); and David Geffen UCLA School of Medicine, Los Angeles (C.J., S.G.V., J.D.C., K.N.-S.). Address reprint requests to Dr. Nielsen-Saines at the Division of Pediatric Infectious Diseases, David Geffen School of Medicine at UCLA, MDCC 22-442, 10833 LeConte Ave., Los Angeles, CA 90095, or at knielsen@mednet.ucla.edu.

This article was published on March 4, 2016, at NEJM.org.

DOI: 10.1056/NEJMoa1602412

Copyright © 2016 Massachusetts Medical Society.

**Z**IKA VIRUS (ZIKV) WAS FIRST IDENTIFIED in Brazil in 2015 by reverse-transcriptase–polymerase-chain-reaction (RT-PCR) assays of serum specimens from patients from the state of Bahia who presented with a denguelike illness that was characterized by rash, fever, myalgias, arthralgias, and conjunctivitis.<sup>1</sup> Soon thereafter, local transmission of ZIKV was reported,<sup>2</sup> and a link for transmission of ZIKV between French Polynesia and Brazil was described.<sup>3</sup> In September 2015, researchers reported a substantial increase in the number of cases of neonatal microcephaly among women giving birth in northeastern Brazil,<sup>4,5</sup> and a subsequent increase was reported in southeast Brazil.<sup>6</sup> ZIKV has been isolated from the amniotic fluid of women who are pregnant with infants who have confirmed microcephaly<sup>4,6,7</sup> and from the brain of a fetus with central nervous system (CNS) abnormalities.<sup>8</sup>

We have been conducting active surveillance for dengue infection in the general population of Rio de Janeiro since 2007. In 2012, we established a prospective cohort for dengue surveillance in mother–infant pairs within the Manguinhos Rio de Janeiro area. In 2015, we noted an increase in cases of a denguelike illness that was characterized by a descending rash, generally without fever; this increase coincided with a surge in the number of cases in northeastern Brazil of illness characterized by a pruriginous rash. In early 2015, most cases were originally reported to surveillance systems as dengue; however, ZIKV was eventually identified.<sup>9</sup> To identify ZIKV cases in our population, we modified our pregnancy cohort study and enrolled women at any week of gestation who presented with a rash. Here we report demographic, clinical, laboratory, and gestational ultrasonographic findings in the cohort of pregnant women enrolled in our ZIKV study to date.

## METHODS

### STUDY POPULATION

In this cohort study, pregnant women at any week of gestation who presented to the acute febrile illness clinic at the Oswaldo Cruz Foundation with a rash that had developed within the previous 5 days were offered enrollment and were included in the study after providing informed consent. After the women were enrolled, detailed demographic, medical, and prenatal history in-

formation, as well as clinical findings, were entered into case-report forms. Information in prenatal records regarding rubella, cytomegalovirus, and Venereal Disease Research Laboratory serologic testing was reviewed. Serum and urine specimens were obtained at study entry. Women had weekly follow-ups by telephone, and a second visit was scheduled within 30 days after enrollment for clinical and laboratory follow-up. Women were referred for fetal ultrasonography before 20 weeks of gestation, between 20 and 30 weeks of gestation, and after 30 weeks of gestation. No women had had diagnoses of fetal malformations in the current pregnancy before enrollment. The study population was generally healthy; the women reported no coexisting conditions or medication use. Infants born to ZIKV-positive mothers will be followed prospectively.

### STUDY OVERSIGHT

The study protocol was approved by the institutional review boards at Fundação Oswaldo Cruz (Fiocruz) and the University of California, Los Angeles. Participants provided written informed consent. The authors vouch for the accuracy and completeness of the data and the analyses and for the fidelity of the study to the protocol.

### LABORATORY TESTING

Real-time RT-PCR assays for ZIKV were performed with the QuantiTect Probe RT-PCR kit (Qiagen), as described previously,<sup>10</sup> with the same primers and cycle times, at the Fiocruz Flavivirus Laboratory; assays were performed on blood specimens, urine specimens, or both that were obtained at the entry visit. The Fiocruz Flavivirus Laboratory is a reference laboratory for flavivirus infections in the region. Serologic testing for IgG antibodies to dengue (Abcam) was performed on the serum specimens obtained at the entry visit.

### FETAL ULTRASONOGRAPHY

All abdominal scanning was performed with a 4-to-8-mHz probe (Voluson 730 Expert/Voluson E6, GE) by perinatologists who were certified by the Brazilian College of Radiology and the Brazilian Federation of Societies of Gynecology and Obstetrics (Febrasgo). The variables that were measured are listed in the Supplementary Appendix, available with the full text of this article at NEJM.org. For Doppler studies, the pulsatility

index of the umbilical artery and of the middle cerebral artery were used.<sup>11</sup> Abnormalities such as cerebral calcifications and microcephaly were noted. Measured fetal ultrasonographic variables were plotted by gestational age according to the nomograms published on [www.perinatology.com](http://www.perinatology.com). Intrauterine growth restriction was defined as fetal weight estimated according to the Hadlock formula that was below the 10th percentile.<sup>12</sup> Microcephaly in fetal imaging was defined as fetal head measurements (e.g., head circumference) that were two standard deviations below the mean expected at a particular gestational age or below the third percentile.<sup>13</sup>

#### STATISTICAL ANALYSIS

We compared the demographic and clinical variables of pregnant women who were positive for ZIKV on PCR with those who were negative for ZIKV on PCR, using Fisher's exact test (two-sided); P values of less than or equal to 0.05 were considered to indicate statistical significance. For comparison of medians, an independent-samples median test was used.

## RESULTS

#### CHARACTERISTICS OF PARTICIPANTS

During the period from September 2015 through February 2016, we enrolled 88 pregnant women and tested blood specimens, urine specimens, or both for ZIKV by qualitative RT-PCR. Of these 88 women, 72 (82%) had positive results for ZIKV on PCR in blood, urine, or both: 60 women had positive PCR results in serum specimens, 46 had positive PCR results in urine samples, and 34 had positive PCR results in both specimens; 12 women had positive results in urine specimens only, and 26 had positive results in blood specimens only (median number of PCR cycles for serum specimens, 33.0; interquartile range, 30.0 to 34.0; range, 24.0 to 37.0; and median number of PCR cycles for urine specimens, 29.0; interquartile range, 26.0 to 31.8; range, 22.0 to 37.0). Demographic and clinical characteristics are described in Table 1. Among ZIKV-positive women, more than half reported similar illnesses in other family members, and 21% reported that their partner had been ill. ZIKV infection was present in women of all socioeconomic strata. More than half the women presented with acute infection in the second trimester of pregnancy.

There were no significant differences in demographic characteristics or medical history between women who were positive for ZIKV and those who were negative for ZIKV. ZIKV-positive women resided across multiple neighborhoods and municipalities within the larger metropolitan Rio de Janeiro area (Fig. S1 in the Supplementary Appendix).

#### CLINICAL PRESENTATION

All pregnant women had rash as part of their clinical presentation, since rash was an inclusion criterion. A descending macular or maculopapular rash was the most common type of exanthem noted in ZIKV-positive women (Fig. 1). The maculopapular rash was seen far more frequently in ZIKV-positive women than in ZIKV-negative women ( $P=0.02$ ). The other prevalent finding was pruritus, which was seen in 94% of the women in our study. The next most common finding was arthralgia, which was reported in 65% of ZIKV-positive women and in 41% of ZIKV-negative women ( $P=0.16$ ). Conjunctival injection was present in 58% of ZIKV-positive women, and in a far smaller percentage (19%) of ZIKV-negative women ( $P=0.002$ ), which suggests that this symptom is a specific clinical feature of ZIKV infection. Lymphadenopathy (isolated or generalized) was found more prominently in women with acute ZIKV infection than in ZIKV-negative women (41% vs. 6%,  $P=0.02$ ). Fever was not a highly prominent finding, occurring in less than a third of women with acute ZIKV-infection. When fever was present, it was generally short-term and low grade (37.5 to 38.0°C). Nausea or vomiting was reported in 21% of ZIKV-positive women and was more common (38%) in ZIKV-negative women ( $P=0.20$ ). Findings consistent with bleeding (primarily gingival) were present in less than 21% of all women. Respiratory findings were rare (7%) in ZIKV-positive women.

#### OUTCOMES OF PREGNANCIES

Two ZIKV-positive women miscarried during the first trimester. Of the 70 remaining women with ZIKV infection, 42 (60%) had prenatal ultrasonographic examinations, with a total of 56 studies performed; 28 women declined imaging studies either because the obstetrical facility was too far away or because of fear of possible fetal abnormalities related to ZIKV infection. ZIKV-negative women had undergone fetal ultrasonography as

<b>Table 1. Baseline Demographic and Clinical Characteristics of Women in the Pregnancy Cohort.</b>			
<b>Variable</b>	<b>ZIKV-Positive Women (N=72)</b>	<b>ZIKV-Negative Women (N=16)</b>	<b>P Value*</b>
<b>Demographics</b>			
Age — yr			0.94†
Median (IQR)	29 (26–34)	28 (26–33)	
Range	17–46	20–36	
Other family members ill — no./total no. (%)	36/64 (56.2)	5/16 (31.2)	0.10
Partner ill — no./total no. (%)	12/57 (21.1)	1/16 (6.2)	0.27
Use of repellent — no./total no. (%)	19/47 (40.4)	3/10 (30.0)	0.73
History of dengue — no./total no. (%)	22/70 (31.4)	9/16 (56.2)	0.08
<b>Socioeconomic status — no./total no. (%)‡</b>			
Income ≤2× minimum wage	24/65 (36.9)	2/13 (15.4)	0.20
Income >2 to ≤5× minimum wage	26/65 (40.0)	5/13 (38.5)	1.00
Income >5× minimum wage	15/65 (23.1)	6/13 (46.2)	0.10
<b>Week of gestation at time of infection</b>			
Median (IQR)	20 (14–26)	17 (10–23)	0.60†
Range	5–38	7–39	
<b>Distribution — no. (%)</b>			
>4 to ≤13 wk	17/72 (23.6)	5/16 (31.2)	0.53
>13 to ≤26 wk	38/72 (52.8)	8/16 (50.0)	1.00
>26 to ≤39 wk	17/72 (23.6)	3/16 (18.8)	1.00
<b>Symptoms — no./total no. (%)</b>			
Rash§	72/72 (100.0)	16/16 (100.0)	
Any			0.47†
Median duration	4	5.5	
Range	2–14	2–60	
Macular	37/72 (51.4)	8/16 (50.0)	1.00
Maculopapular	32/72 (44.4)	2/16 (12.5)	0.02
Other	3/72 (4.2)	6/16 (37.5)	0.001
Pruritus	69/72 (95.8)	14/15 (93.3)	0.54
Arthralgia or arthritis	46/72 (63.9)	7/16 (43.8)	0.16
Conjunctival injection	42/72 (58.3)	2/15 (13.3)	0.002
Headache	38/72 (52.8)	9/16 (56.3)	1.00
Fatigue or malaise	35/72 (48.6)	7/16 (43.8)	0.79
Retro-orbital pain	34/69 (49.3)	5/16 (31.3)	0.27
Myalgia	30/72 (41.7)	8/16 (50.0)	0.59
Lymphadenopathy	29/72 (40.3)	1/15 (6.7)	0.015
Localized	15/29 (51.7)	0/1	1.00
Generalized	14/29 (48.3)	1/1 (100.0)	1.00
Paresthesia	27/58 (46.6)	4/10 (40.0)	0.75
Edema	23/64 (35.9)	4/16 (25.0)	0.56

**Table 1. (Continued.)**

Variable	ZIKV-Positive Women (N=72)	ZIKV-Negative Women (N=16)	P Value*
Fever	20/72 (27.8)	2/16 (12.5)	0.34
Duration <24 hr	12/20 (60.0)	0/2	0.20
Duration ≥24 to <72 hr	8/20 (40.0)	2/2(100.0)	0.20
Median temperature (range) — °C	37.6 (37.5–38.0)	38.2 (37.5–39.0)	1.00†
Photophobia	17/72 (23.6)	5/16 (31.2)	0.53
Anorexia	16/72 (22.2)	2/16 (12.5)	0.51
Diarrhea	16/72 (22.2)	5/16 (31.2)	0.52
Nausea or vomiting	15/72 (20.8)	6/16 (37.5)	0.20
Bleeding, petechia, or enanthema	15/72 (20.8)	2/16 (12.5)	0.73
Abdominal pain	9/71 (12.7)	1/16 (6.2)	0.68
Dizziness or light-headedness	8/71 (11.3)	1/16 (6.2)	1.00
Respiratory symptoms: coryza, cough, or sore throat	5/72 (6.9)	3/16 (18.8)	0.16
Dysuria	1/69 (1.4)	0/16	1.00

\* P values were calculated with Fisher’s exact test (two-sided), except as otherwise noted.

† The P value was calculated with the use of an independent-samples median test.

‡ The Brazilian minimum monthly wage is \$880 in Brazilian reals.

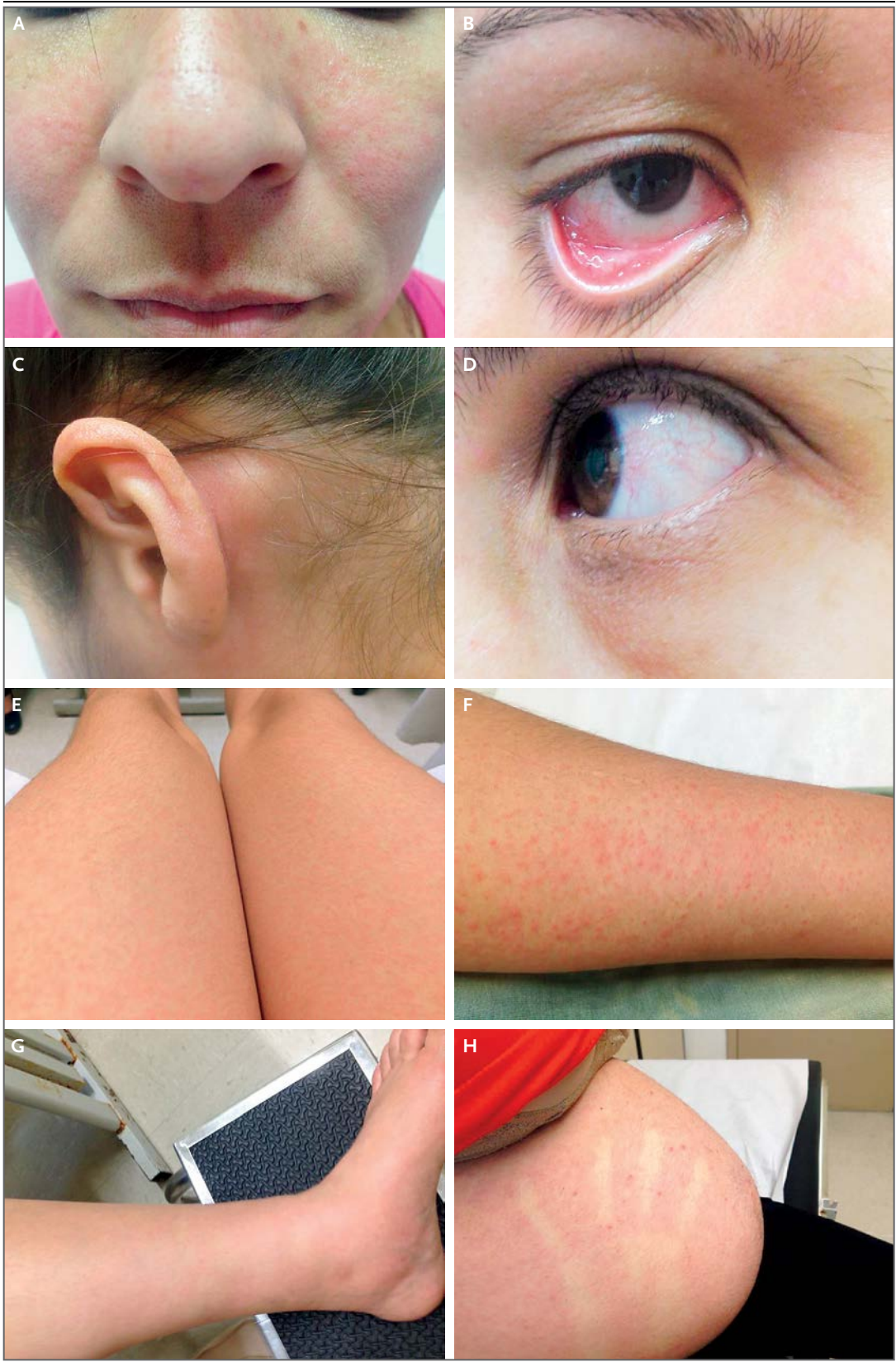§ Rash was an inclusion criterion.

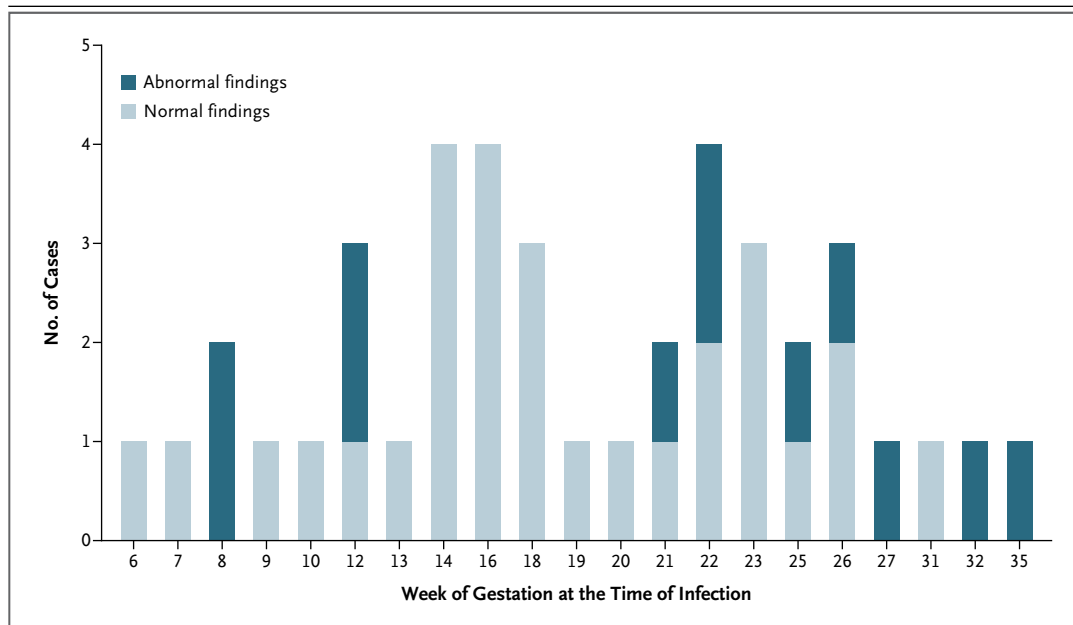
part of regular prenatal care, and the results were reported as normal. All the women in the cohort had received prenatal care; immunity to rubella and cytomegalovirus was documented, and none of the women had syphilis; 88% of the women had positive results for dengue-specific IgG antibodies at study entry.

As seen in Figure 2 and Table 2, the timing of acute ZIKV infection ranged from 6 to 35 weeks of gestation among the 42 women in whom fetal ultrasonography was performed. Abnormal results on ultrasonography or Doppler studies were seen in 12 cases (29%). Five of the 12 fetuses had intrauterine growth restriction, as determined by ultrasonography, with or without accompanying microcephaly. Cerebral calcifications were noted in 4 fetuses and other CNS alterations in 2 fetuses. Abnormal arterial flow in the cerebral or umbilical arteries was seen in 4 fetuses. Oligohydramnios and anhydramnios were seen in two cases. There were two fetal deaths after 30 weeks of gestation, which were detected by ultrasonography performed in one woman who had been infected at 25 weeks of gestation and in a second woman who had been infected at 32 weeks of gestation. One fetus was found to have additional

malformations, including agenesis of the vermis, Blake’s pouch cyst, and potentially a club foot, in addition to cerebral calcifications, intrauterine growth restriction, and microcephaly (genetic findings have been negative). The mothers of this fetus and of another fetus with intrauterine growth restriction and accompanying cerebral calcifications were infected in the first trimester of pregnancy. Cerebral calcifications were also seen in fetuses of women infected as late as 27 weeks, and intrauterine growth restriction was present in fetuses of women infected within a wide range of infant gestational age. (For ultrasonographic findings and clinical features of infants born to date and for an ultrasound of a fetus with cerebral calcifications, see Table S1 and Figure S2 in the Supplementary Appendix.) Figure 3 shows plots of ultrasonographic measures for fetuses of ZIKV-positive pregnant women (also see Fig. S3 in the Supplementary Appendix).

At the time of this preliminary report, six live births and two stillbirths have occurred (Infants 2, 3, 10, 12, 19, 23, 36, and 53) (Table 2 and Table S1 in the Supplementary Appendix). Two infants with normal ultrasonographic results





**Figure 2. Week of Gestation at the Time of ZIKV Infection and Abnormal Ultrasonographic and Doppler Findings.** Twelve of 42 women (29%) in whom fetal ultrasonography was performed had abnormal findings.

had normal measures and a normal physical examination at birth (Infants 2 and 3). Two infants with an ultrasonographic diagnosis of fetal death were delivered stillborn (Infants 10 and 53). Infant 19 was born at term with severe microcephaly; computed tomography of the brain confirmed ultrasonographic findings of cerebral calcifications and global cerebral atrophy. Funduscopic exam showed macular hypoplasia of the left eye and macular scarring on the right eye. Infant 12 was delivered prematurely by cesarean section because of severe intrauterine growth restriction, oligohydramnios, and placental insufficiency and was found to be small for gestational age, with a head circumference below the 5th percentile for gestational age. Funduscopic examination showed macular hypoplasia. Infant

23 was delivered on an emergency basis owing to anhydramnios and was found to have normal growth measures despite the suggestion of intrauterine growth restriction on ultrasonography performed at 40 weeks. This infant was found to be lethargic with poor sucking reflexes at birth; electroencephalography during the infant's stay in the neonatal intensive care unit (NICU) showed nonspecific findings, but the infant has done well. Infant 36 had intrauterine growth restriction on ultrasonography and was small for gestational age at the time of birth. The head circumference was proportional to the small body size. This infant is currently in the NICU.

## DISCUSSION

ZIKV is a flavivirus that was recently introduced into Brazil. Its rapid expansion into a population that is probably fully susceptible is due to the effectiveness of its vector, the *Aedes aegypti* mosquito. Diagnosis of ZIKV infection in Brazil has been complicated by the cross-reactivity between flavivirus antibodies and by the fact that dengue has been endemic in Brazil for more than 30 years. Serosurveillance studies have found evidence of dengue antibodies in more than 90% of the population of Recife.<sup>14</sup> In our cohort, dengue IgG

**Figure 1 (facing page). Clinical features of Zika Virus Infection in Pregnant Women.**

Panel A shows a maculopapular rash on the face; Panel B, conjunctival and palpebral erythema; Panel C, retroauricular lymphadenopathy; Panel D, conjunctival injection with prominence of vasculature; Panel E, a rash on the legs, with a lacy reticular pattern; Panel F, a maculopapular rash on the inner arm; Panel G, edema of the foot, which the patient reported was painful; and Panel H, a blanching macular rash on the gravid abdomen.

**Table 2. Ultrasonographic Features of Fetuses and Findings at Birth.\***

Fetus No.	Week of Gestation at Infection	Week of Gestation at Ultrasound Examination	Abnormal Findings on Doppler Ultrasonography	Findings at Birth
19	8	35	Microcephaly, cerebral calcifications, abnormal middle cerebral artery, intrauterine growth restriction	Microcephaly, cerebral calcifications on CT, global cerebral atrophy, macular lesions
40	8	20	Choroid plexus cyst, cerebellar atrophy (transverse diameter <5th percentile)	Still in utero
24	12	29	Microcephaly, cerebral calcification, Blake's cyst, agenesis vermis, club foot, intrauterine growth restriction	Still in utero
41	12	24	Mega cisterna magna (>95th percentile)	Still in utero
39	21	30	Cerebellar and cerebral right periventricular calcifications	Still in utero
17	22	26	Middle cerebral artery flow <5th percentile	Still in utero
12	22	27	Microcephaly, placental insufficiency as assessed by Doppler study, oligohydramnios, intrauterine growth restriction	Small for gestational age, head circumference proportional to body size, macular lesions
10	25	30	Normal first ultrasonogram, fetal death detected at 36 weeks on repeat ultrasonogram	Stillbirth
36	26	35	Microcephaly, abnormal umbilical artery flow (>95th percentile on the pulsatile index), intrauterine growth restriction	Small for gestational age, head circumference proportional to body size
38	27	35	Cerebral calcifications, ventriculomegaly, brachycephaly	Still in utero
2	30	34	None	Normal at birth
3	31	33	None	Normal at birth
53	32	38	Fetal death	Stillbirth
23	35	40	Anhydramnios, intrauterine growth restriction	Normal growth measure, poor sucking reflex, EEG abnormalities

\* EEG denotes electroencephalogram, and CT computed tomography.

antibodies were present in 88% of the women. The diagnosis of ZIKV in Brazil relies on identification of the virus through RT-PCR during the acute period of infection. The virus is detectable in blood during the period of acute viremia and initial symptoms and subsequently is shed in the urine, generally for 3 to 14 days.<sup>15</sup> Because RT-PCR assays for ZIKV are generally not available, most cases of ZIKV infection in Brazil are diagnosed clinically, without laboratory confirmation. In our cohort, all 72 women who were positive for ZIKV had acute infection with virus that was detected in blood, urine, or both. As compared with women who tested negative for acute ZIKV infection, women who tested positive for the virus had distinctive clinical features of ZIKV infection that included conjunctival injection,

lymphadenopathy, and absence of respiratory symptoms. These clinical features, in addition to a macular or maculopapular rash with pruritus, should raise the suspicion for ZIKV infection. Low-grade fever was found in only 28% of the women; therefore a case definition that is based on the presence of fever would miss more than 70% of cases.<sup>16</sup>

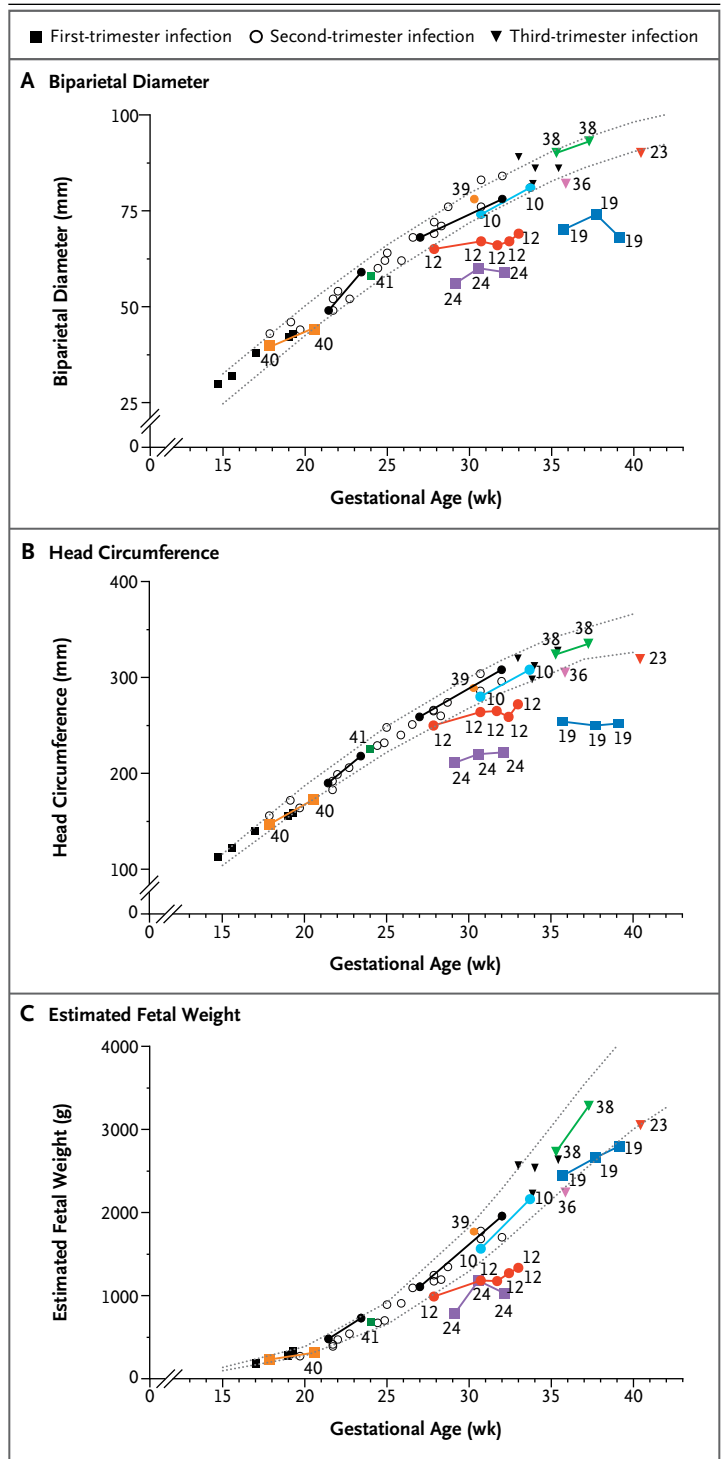
Whether sexual transmission of ZIKV played a role in transmission to pregnant women in our cohort is difficult to assess, since couples usually cohabit and would presumably have the same type of vector exposure. ZIKV-positive women more frequently had a history of a symptomatic partner than did ZIKV-negative women; however, this could also be due to less exposure to the vector among uninfected couples.



**Figure 3. Fetal Biometric Variables as Measured on Ultrasonography.**

Fetal measurements for each fetus, plotted according to gestational age, are shown for biparietal diameter (Panel A), head circumference (Panel B), and estimated fetal weight (Panel C). Dotted lines show the 10th and 90th percentiles for gestational age, based on established nomograms from Perinatology.com. Fetal weight curves are based on the Hadlock formula, in which a measurement of less than the 10th percentile is considered to indicate fetal growth restriction. Microcephaly was defined as a head circumference below the third percentile, or more than 2 standard deviations below the mean expected for gestational age. Symbols denote the trimester of PCR-documented infection (first trimester, <14 weeks; second trimester, 14 to 25 weeks; third trimester, ≥26 weeks). Repeat measurements for the same fetus are connected with a solid line to show growth trajectory. Results for fetuses with abnormal findings are denoted in color and labeled with the fetus number. Not all measurements were obtained for every fetus at each ultrasound examination.

Links between the current ZIKV epidemic in Brazil and the rise in the number of observed cases of neonatal microcephaly have been discussed in both the scientific literature and the lay press and have generated considerable debate about whether the observed phenomenon is real, and, if so, whether microcephaly is a direct effect of ZIKV or whether it could be due to potential environmental exposure of pregnant women to teratogenic agents.<sup>17</sup> Ultrasonographic findings in our cohort showed serious and frequent problems in fetal and central nervous system development, affecting 29% of the 42 women whose fetuses were evaluated by ultrasonography. Abnormalities were noted in the fetuses of women who were infected at any week of gestation. Fetuses infected in the first trimester had findings suggestive of pathologic change during embryogenesis, but CNS abnormalities were also seen in fetuses infected as late as 27 weeks of gestation. Findings suggestive of placental insufficiency were identified in fetuses with intrauterine growth restriction and infections occurring at later gestational ages. There were two cases of late fetal death. Microcephaly as detected by ultrasonography and confirmed at birth was noted, but in only one case was it an isolated finding that was not present in conjunction with intrauterine growth restriction. Microcephaly in our cohort was mainly part of an overall composite of restricted fetal growth and not an asymmetric,



isolated finding. Although microcephaly has been widely discussed in relation to ZIKV infection in Brazil, it is important to note that other findings such as cerebral calcifications and intrauterine growth restriction were frequently present.

Our findings are worrisome because 29% of ultrasonograms showed abnormalities, including intrauterine growth restriction, CNS findings, and fetal death, in fetuses of women with PCR-positive ZIKV infection. These were all healthy women with no other risk factors for adverse pregnancy outcomes. In a prior study of 662 pregnancies in HIV-infected women who were followed for 9 years in Rio de Janeiro, we noted a stillbirth rate of 2.5% and 13 mild-to-moderate infant malformations (2%), none of which occurred more than once.<sup>18</sup> In the present scenario, over a period of a few months, we identified a fetal death rate of 4.8% — nearly twice the rate in an HIV-infected pregnant cohort followed for a decade — in addition to the serious fetal developmental problems.

To date six live births have occurred: two infants with normal ultrasonographic results had normal measures and normal examinations at birth; one infant had severe microcephaly and global cerebral atrophy as identified prenatally; two infants with growth restriction in utero were found to be small for gestational age at delivery with proportionally small heads, and one infant with anhydramnios was found to have normal measures at birth.

Our findings point to a link between ZIKV and abnormal fetal and placental development or placental insufficiency in a subgroup of ZIKV-positive women in whom fetal ultrasonography was performed. None of the 16 women who tested negative for acute ZIKV infection had abnormal results on fetal ultrasonography. Although the size of our control group was small and the ZIKV-negative women presumably had alternative processes for their rash, these women lived in the same geographic area as ZIKV-positive women and are likely to have had environmental exposures that were similar to those of ZIKV-positive women.

Our observations suggest that many aspects of ZIKV infection are similar to those of rubella, particularly rash, arthralgias, pruritus, and lymph-

adenopathy in the mother without high fever. About 85% of babies with congenital rubella in the U.S. pandemic of 1959–1965 had intrauterine growth restriction.<sup>19</sup> In congenital rubella, specific organs are small because they have a subnormal number of cells, but the cytoplasmic mass of individual cells is within normal limits<sup>19,20</sup>; in contrast, in intrauterine growth restriction due to maternal malnutrition, for example, the number of cells is normal but the cells contain less cytoplasm. A major difference of concern between ZIKV infections in Brazil in 2015–2016 and rubella virus infections in the U.S. pandemic of 1959–1965 is the level of population immunity. In Brazil in 2015–2016, none of the population has antibodies to ZIKV. In contrast, in the United States during the rubella epidemic, there were 20,000 cases of the congenital rubella syndrome, but in 1959 only 17.5% of women of childbearing age lacked rubella antibodies.<sup>21</sup>

In summary, we believe that our findings provide further support for a link between maternal ZIKV infection and fetal and placental abnormalities that is not unlike that of other viruses that are known to cause congenital infections characterized by intrauterine growth restriction and placental insufficiency. Women with suspected or confirmed ZIKV infection should be monitored closely, with serial ultrasonography to evaluate for signs of placental insufficiency, given the risks of fetal death and intrauterine growth restriction. The establishment of a scientifically credible link between ZIKV and abnormal congenital findings is of utmost importance for the effective and successful management of this epidemic in Brazil and worldwide.

This study was not supported by any research funds.

Disclosure forms provided by the authors are available with the full text of this article at NEJM.org.

We thank the women who enrolled in this study, Mr. Marcelos Santos for assistance with the graphics of one of our figures, Dr. Yvonne Bryson for her ongoing support of our study, and Drs. Celina Boga and Eliane Chaves Vianna of the Centro de Saúde Escola Germano Sinalva Faria—ENSP/FIOCRUZ for their continued support of our pregnancy cohort study.

## REFERENCES

- Campos GS, Bandeira AC, Sardi SI. Zika virus outbreak, Bahia, Brazil. *Emerg Infect Dis* 2015;21:1885-6.
- Zanluca C, de Melo VC, Mosimann AL, Dos Santos GI, Dos Santos CN, Luz K. First report of autochthonous transmission of Zika virus in Brazil. *Mem Inst Oswaldo Cruz* 2015;110:569-72.
- Musso D. Zika virus transmission from French Polynesia to Brazil. *Emerg Infect Dis* 2015;21:1887.
- Oliveira Melo AS, Malinger G, Ximenes R, Szejnfeld PO, Alves Sampaio S, Bispo de Filippis AM. Zika virus intrauterine infection causes fetal brain abnormality and microcephaly: tip of the iceberg? *Ultrasound Obstet Gynecol* 2016; 47:6-7.
- Ventura CV, Maia M, Bravo-Filho V, Góis AL, Belfort R Jr. Zika virus in Brazil and macular atrophy in a child with microcephaly. *Lancet* 2016;387:228.
- Possible association between Zika virus infection and microcephaly — Brazil,

2015. *MMWR Morb Mortal Wkly Rep* 2016;65:59-62.
7. Calvet G, Aguiar RS, Melo AS, et al. Detection and sequencing of Zika virus from amniotic fluid of fetuses with microcephaly in Brazil: a case study. *Lancet Infect Dis* 2016 February 17 (Epub ahead of print).
8. Mlakar J, Korva M, Tul N, et al. Zika virus associated with microcephaly. *N Engl J Med*. DOI: 10.1056/NEJMoa1600651.
9. Calvet GA, Filippis AM, Mendonça MC, et al. First detection of autochthonous Zika virus transmission in a HIV-infected patient in Rio de Janeiro, Brazil. *J Clin Virol* 2016;74:1-3.
10. Lanciotti RS, Kosoy OL, Laven JJ, et al. Genetic and serologic properties of Zika virus associated with an epidemic, Yap State, Micronesia, 2007. *Emerg Infect Dis* 2008;14:1232-9.
11. Ebbing C, Rasmussen S, Kiserud T. Middle cerebral artery blood flow velocities and pulsatility index and the cerebroplacental pulsatility ratio: longitudinal reference ranges and terms for serial measurements. *Ultrasound Obstet Gynecol* 2007;30:287-96.
12. Gardosi J, Chang A, Kalyan B, Sahota D, Symonds EM. Customised antenatal growth charts. *Lancet* 1992;339:283-7.
13. Tarrant A, Garel C, Germanaud D, et al. Microcephaly: a radiological review. *Pediatr Radiol* 2009;39:772-80.
14. Castanha PM, Cordeiro MT, Martelli CM, Souza WV, Marques ET Jr, Braga C. Force of infection of dengue serotypes in a population-based study in the northeast of Brazil. *Epidemiol Infect* 2013;141:1080-8.
15. Gourinat AC, O'Connor O, Calvez E, Goarant C, Dupont-Rouzeyrol M. Detection of Zika virus in urine. *Emerg Infect Dis* 2015;21:84-6.
16. Epidemiological alert: neurological syndrome, congenital malformations, and Zika virus infection — implications for public health in the Americas. Washington, DC: Pan American Health Organization, December 1, 2015.
17. Butler D. Zika virus: Brazil's surge in small-headed babies questioned by report. *Nature* 2016;530:13-4.
18. Calvet GA, João EC, Nielsen-Saines K, et al. Trends in a cohort of HIV-infected pregnant women in Rio de Janeiro, 1996-2004. *Rev Bras Epidemiol* 2007;10:323-37.
19. Naeye RL, Blanc W. Pathogenesis of congenital rubella. *JAMA* 1965;194:1277-83.
20. Plotkin SA, Boue A, Boue JG. The in vitro growth of rubella virus in human embryo cells. *Am J Epidemiol* 1965;81:71-85.
21. Sever JL, Schiff GM, Huebner RJ. Frequency of rubella antibody among pregnant women and other human and animal populations: a report from the Collaborative Study of Cerebral Palsy. *Obstet Gynecol* 1964;23:153-9.

Copyright © 2016 Massachusetts Medical Society.